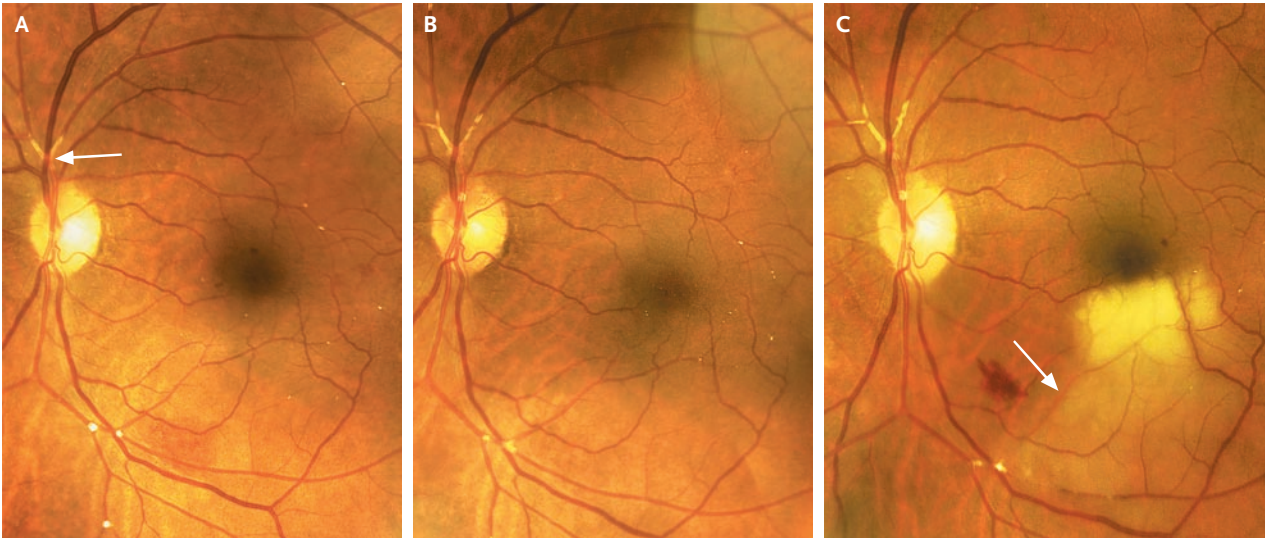


## IMAGES IN CLINICAL MEDICINE

## Retinal Arteriolar Cholesterol Emboli



Michael Colucciello, M.D.

South Jersey Eye Physicians  
Moorestown, NJ 08057  
michael@macula.us

**A** 59-YEAR-OLD MAN WITH A MEDICAL HISTORY OF HYPERTENSION, HYPERlipidemia, and coronary artery disease presented with transient, painless visual obscuration in the left eye, and he was referred for retinal evaluation. Two months earlier, he had undergone placement of a stent in the left carotid artery for severe stenosis. He was receiving antiplatelet therapy. Two years earlier, an eye examination had been unremarkable. Retinal examination of the left eye showed multiple, tiny refractile retinal arteriolar cholesterol emboli and a saddle embolus superior to the optic nerve (Panel A, arrow). Two months later, repeat examination showed an increase in the number of cholesterol emboli (Panel B). The patient's visual acuity was unchanged (20/25 bilaterally). Four weeks later, a sudden, painless loss of the left superior visual field occurred. Examination revealed whitening in the inferior macular region (Panel C, arrow), a finding that was consistent with an occlusion at the second major bifurcation of the inferior temporal branch of the retinal artery. After carotid stenting, ongoing deposition of retinal emboli may occur. The patient was left with a deficit in the superior visual field.

Copyright © 2008 Massachusetts Medical Society.

## WEB-ONLY IMAGES IN CLINICAL MEDICINE

Click on "Featured Images" at [www.nejm.org](http://www.nejm.org) to see the *Journal's* Web-only Images in Clinical Medicine. The Images are listed (with e page numbers) in the table of contents of the printed *Journal* the week they are published and are compiled on the *Journal's* Web site.